

Preliminary Report

# Improving Outcomes in Upper Arm Liposuction: Adding Radiofrequency-Assisted Liposuction to Induce Skin Contraction

Aesthetic Surgery Journal  
32(1) 84–95  
© 2012 The American Society for  
Aesthetic Plastic Surgery, Inc.  
Reprints and permission:  
[http://www.sagepub.com/  
journalsPermissions.nav](http://www.sagepub.com/journalsPermissions.nav)  
DOI: 10.1177/1090820X11429549  
[www.aestheticsurgeryjournal.com](http://www.aestheticsurgeryjournal.com)  


Diane Irvine Duncan, MD, FACS

**Abstract**

**Background:** Brachioplasty is frequently recommended for patients with more skin laxity than subcutaneous fat. However, many patients are reluctant to accept a visible scar that will affect the activity of the upper arm or clothing choices. Traditional liposuction is effective when minimal skin laxity is present, but the dual problems of postoperative residual skin laxity and unsatisfactory contour irregularities are common when upper arm skin laxity is the chief complaint.

**Objectives:** The author investigates the degree of skin contraction resulting from treatment with radiofrequency-assisted liposuction (RFAL) and attempts to determine whether, after long-term follow-up, the classification of upper arm deformities and their corresponding treatment protocols can be refined to offer patients with prominent skin laxity an alternative to traditional brachioplasty.

**Methods:** A prospective, institutional review board–approved pilot study was planned with 12 consecutive patients who presented to the author’s private clinic for treatment of upper arm laxity. Patients were included only if they were categorized as Stage 2b, 3, or 4 according to the El Khatib and Teimourian system. Based on the “pinch” test and the vertical measurement of skin distal to the bicipital groove as described by El Khatib, a novel caliper was devised to quantify the shortening of the pendulous volar skin. Treatment regions were tattooed prior to surgery and measurements from a Vectra system (Canfield Scientific, Inc., Fairfield, New Jersey) confirmed the preoperative surface area. All patients were treated with the BodyTite device (Invasix, Inc., Yokneam, Israel). No patient underwent skin resection in the volar treatment region. Skin contraction was measured at one year posttreatment. Statistical analysis was conducted with a paired t-test.

**Results:** One year after treatment with RFAL, the mean surface area reduction in the volar upper arm region was 33.5% bilaterally. The mean degree of pendulous vertical “hang” shortening was 50% bilaterally. Statistical analysis showed a *P* value of >.001 for both measurements.

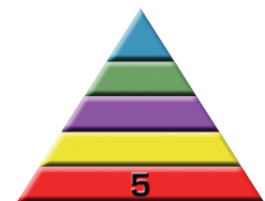**Conclusions:** Treatment with RFAL achieved statistically significant skin contraction in the upper arm region. Patients in categories 2b and 4 were successfully treated with RFAL instead of traditional brachioplasty (which is recommended by the current classification system). Category 3 patients, however, did require a short-scar brachioplasty procedure to obtain satisfactory results.

**Level of Evidence:** 5

**Keywords**

liposuction, body contouring, upper arm, RFAL

Accepted for publication May 5, 2011.



Historically, the classification of upper arm deformities has been limited to descriptions of varying degrees of brachial ptosis. In previous articles from El Khatib<sup>1</sup> and Teimourian and Malekzadeh,<sup>2</sup> patients presenting for upper arm contouring were categorized into various stages according to their degree of skin laxity plus or minus lipodystrophy; both authors then provided treatment algorithms for each stage (Table 1). Appelt et al<sup>3</sup> presented a more extensive classification based on the specific location of laxity and recommended a certain type of brachioplasty patients in each

category. With regard to assessing a patient’s degree of ptosis, El Khatib measured the vertical height of pendulous skin, caudal to the bicipital groove. The proportion of hanging skin

Dr. Duncan is in private practice in Fort Collins, Colorado.

**Corresponding Author:**

Dr. Diane Duncan, Plastic Surgical Associates of Fort Collins, 1701 East Prospect Road, Fort Collins, Colorado 80525 USA.  
Email: [momsurg@aol.com](mailto:momsurg@aol.com)

**Table 1.** Treatment Guidelines: Liposuction Versus Brachioplasty

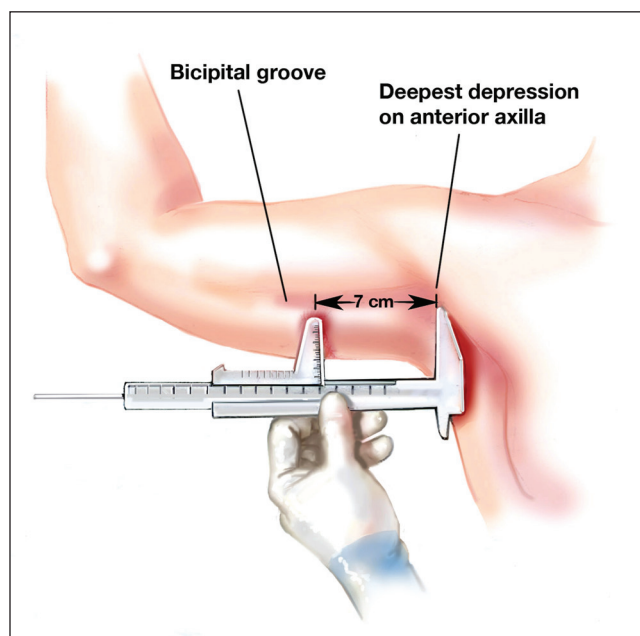
Clinical Appearance	Classification	Recommended Treatment
Minimal fat <250 mL, no ptosis	Stage 1	Circumferential liposuction
Moderate fat with grade 1 ptosis, <5 cm	Stage 2a	Liposuction in two sessions
Moderate to severe fat, Grade 2 ptosis, 5-10 cm	Stage 2b	Distal liposuction, proximal short-scar brachioplasty
Extreme lipodystrophy with Grade 3 ptosis >10 cm	Stage 3	Liposuction plus brachioplasty
Mild to moderate fat with severe Grade 3 ptosis	Stage 4	Traditional brachioplasty

Adapted from El Khatib<sup>1</sup> and Teimourian and Malekzadeh.<sup>2</sup>

relative to the thickness at the base<sup>4</sup> has also been used as a guideline for treatment. Performing a preoperative “pinch” test is also common, which involves placing the patient’s arm in an extended position and pinching the base of the upper arm skin immediately under the biceps and triceps muscles. If the skin touches the webbed space of the evaluator’s hand, a brachioplasty is deemed necessary. A variant of this test was described by Sacks<sup>5</sup> in 2003.

Patients who have laxity but desire smooth, toned upper arms are frequently unable to obtain improvement in their appearance with diet and exercise alone, perhaps because few patients qualify as having a Stage 1 or Stage 2a degree of ptosis (which, in essence, designates minimal-to-moderate fat excess and skin laxity). Most patients who present for upper arm contouring in the United States are classified as Stage 2b, 3, or 4 (according to personal communication with Dr. JP Rubin, November 2011), and the treatment protocol for these patients involves brachioplasty. However, many patients are reluctant to undergo treatment with brachioplasty, discouraged by the appearance of a long scar, and they may choose to avoid treatment. Furthermore, surgeons who treat patients with upper arm lipodystrophy and significant skin laxity have been limited for many years to only two choices: some form of excisional dermolipectomy and traditional liposuction. In most cases, liposuction alone addresses the excess fat, but it does not aesthetically improve the unclothed appearance of the upper arm due to residual postoperative skin laxity and postoperative contour irregularities.

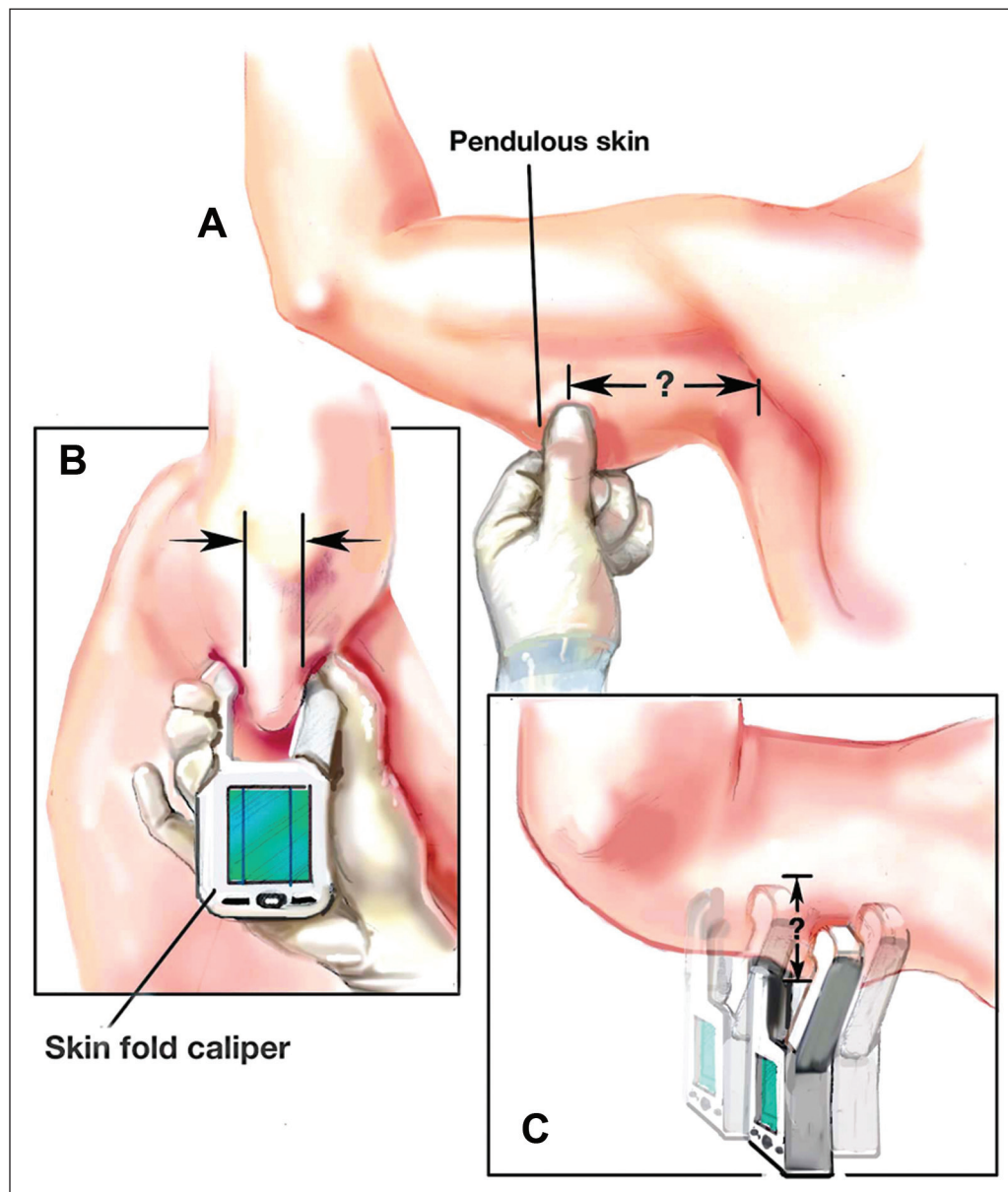
To that end, this article describes a study of the degree of skin contraction resulting from treatment with radio-frequency-assisted liposuction (RFAL) in an attempt to determine whether, after long-term follow-up, the classification of upper arm deformities and their corresponding treatment protocols can be refined to offer patients with prominent skin laxity an alternative to traditional brachioplasty.



**Figure 1.** The skin caliper protrusion device utilizes a digital approximating skin caliper at the base of the bicipital and triceps groove to set a fixed base measurement. The point of placement is standardized at 7 cm distal to the deepest anterior axillary depression. Although not perfectly accurate, it gives a more standardized measurement than a ruler, the “pinch” test, or conventional skin calipers.

## METHODS

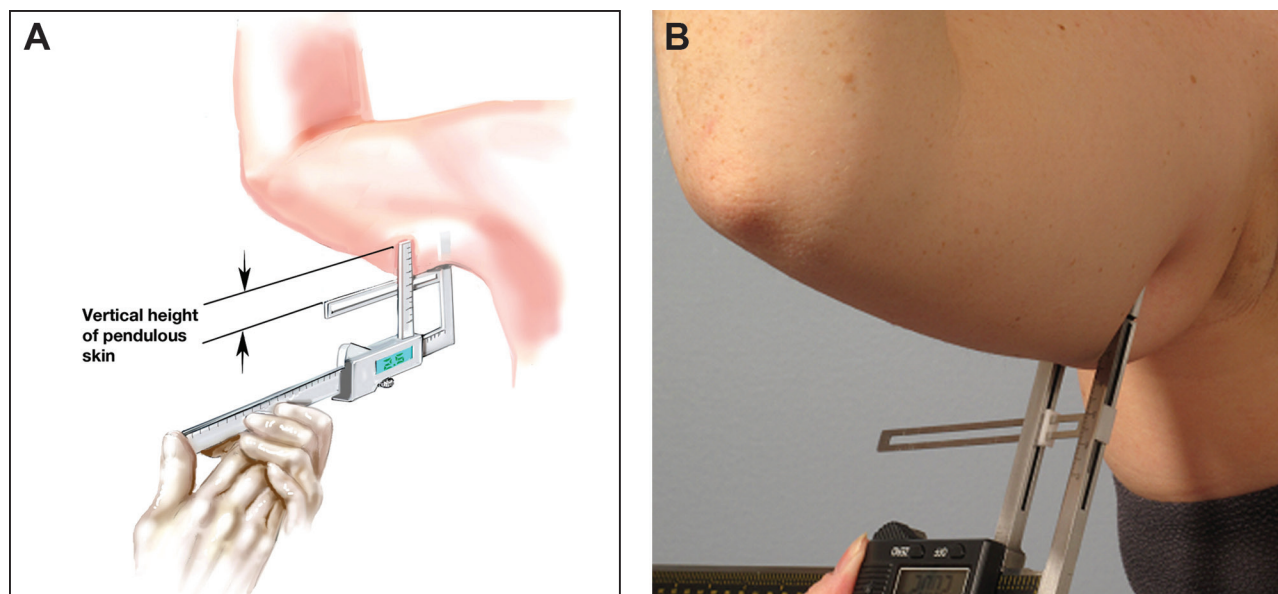
The study was performed under the oversight of the Essex Investigational Review Board (IRB), an independent IRB (Lebanon, New Jersey). Twelve female patients who presented to the author’s private clinic for improvement of their upper arm contours were selected for this study. Patients were included only if they were categorized as Stage 2b, 3, or 4 according to the El Khatib<sup>1</sup> and Teimourian and Malekzadeh<sup>2</sup> system. Classification of each patient’s deformity was based on the parameters described by Teimourian and El Khatib, with adaptations in two areas: (1) the vertical height ptosis measurement method was changed to a skin protrusion measurement, calculated with skin protrusion calipers at a fixed and reproducible point, and (2) classification of Stage 4 patients was altered to include any patient with less than 300 mL of excess fat. Patients were excluded if they were unwilling to be followed up for at least one year and accept tattoos with permanent ink in the volar arm region (which could be later removed with a dermal punch or Yag laser). Other exclusion criteria were current pregnancy; current breastfeeding; a history of previous liposuction, surgery, or injection lipolysis in the upper arm region; open sores or lesions in the treatment region; and unrealistic expectations. All patients selected for the study were informed of the study parameters and signed an informed consent document, along with a separate operative consent prior to treatment.



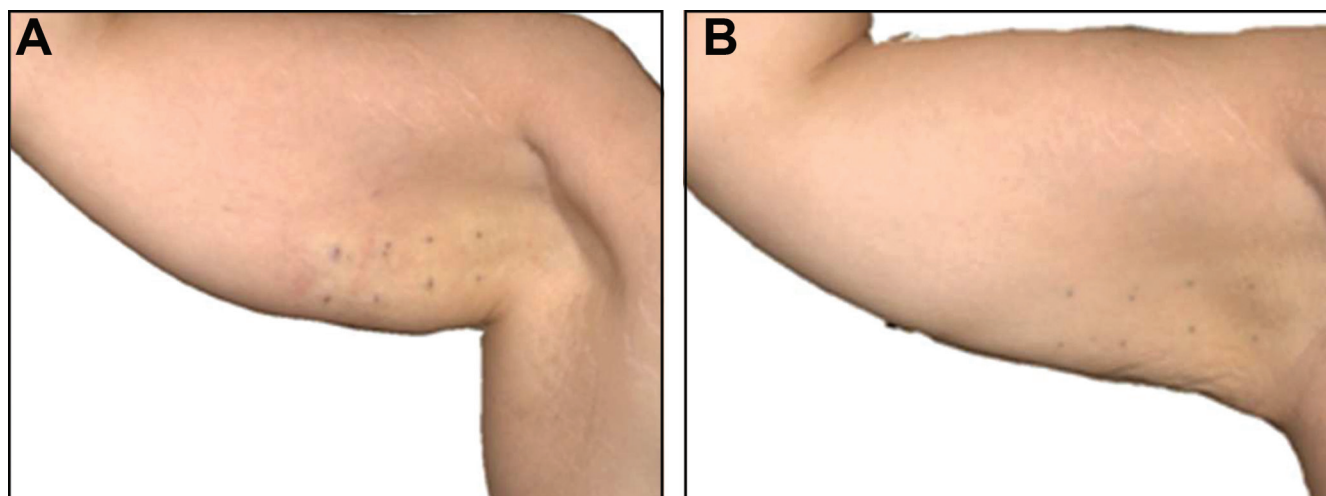
**Figure 2.** The traditional method of measuring skin laxity is shown. (A) The “pinch” test. The examiner pinches together pendulous skin that hangs down below the bicipital groove in order to determine the need for brachioplasty. This test is inaccurate, as the distance from the site of pinch to the axilla is not noted, measurements are not taken, and it is very subjective. (B) Skin fold calipers measure the thickness of the skin and subcutaneous fat when the two prongs are approximated. One variable is the pressure with which the prongs are approximated. A firm pinch creates a “thinner” measurement, while looser approximation will create an apparently thicker subcutaneous measurement. (C) Traditional skin fold calipers are unable to measure the degree of pendulosity of the lax arm skin.

A pretreatment screening evaluation was completed by each patient. The vertical height of each patient’s arm ptosis was measured with the unique skin caliper protrusion device, as stated previously (Figure 1). This device, which utilized a digital approximating skin caliper, was placed at the bicipital ridge anteriorly and the tricipital ridge posteriorly. This point of placement was standardized at 7 cm distal to the area of deepest anterior axillary depression. This caliper provides more standardized meas-

urement than a ruler, the “pinch” test, or conventional skin calipers (Figure 2). The skin caliper portion of the device (Figure 3) was approximated to 2.5 cm, after which the hem gauge portion of the caliper was utilized to measure the degree of vertical pendulous protrusion. These measurements were later compared to the same measurement taken at one year postoperatively. To assess postoperative skin contraction, each patient was also preoperatively marked with a tattoo. Patients were assigned a 2 × 2-cm



**Figure 3.** (A) After setting the digital caliper to approximately 2.5 cm, the hem gauge portion of the device slides up and down to measure the length of vertical skin that hangs below the points of the skin caliper. These measurements were later compared to the same measurement taken one year postoperatively. (B) The same measurement method is shown on a patient from this series.



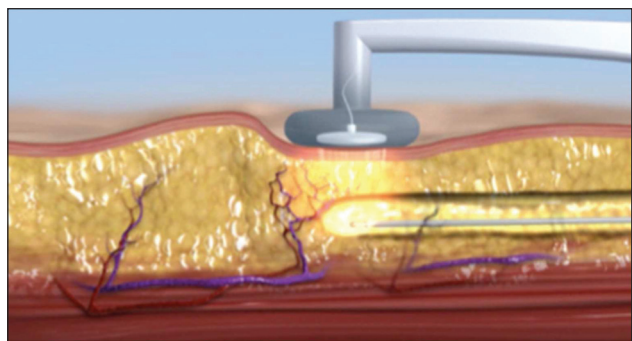
**Figure 4.** One patient in this series demonstrates the tattoo pattern marked preoperatively to assess skin tightening after treatment with radiofrequency-assisted liposuction (RFAL). She is shown (A) preoperatively and (B) one year after treatment. Photographs were captured with the Canfield Vectra system, and surface area calculations were performed with objective computerized measurements.

or 3 × 3-cm tattoo design based on their degree of preoperative skin ptosis and the surface area needing reduction. Seven patients received 3 × 3-cm tattoos placed in the proximal and distal upper arms bilaterally, whereas five patients received 2 × 2-cm tattoos placed in a similar pattern (Figure 4).

Patients were treated with the BodyTite device (Invasix Ltd., Toronto, Ontario), which features a probe with a

distal cannula that contacts the subcutaneous fat directly to simultaneously deliver fat-coagulating and liquefying energy.<sup>6</sup> The radiofrequency (RF) energy also causes the fibrous septae surrounding the fat globules to contract, similar to what can be observed when applying a Bovie cautery device to reduce small periorbital fat deposits. When delivered at varying, stratified depths, this RF energy has the effect of tightening the connection of the





**Figure 5.** The Invasix BodyTite handpiece is shown. This device utilizes an internal cannula with a tip that emits simultaneous radiofrequency energy and suction, as well as an overlying external electrode that reflects heat into the dermis of the skin in the treatment region. An “ironing” motion is used to heat the tissue in the region needing fat emulsification and skin contraction. Diagram provided by Invasix Ltd., the device’s manufacturer. Reprinted with permission.

skin/fat layer to the underlying fascia as well as the overlying dermis. In this way, the quality of the patient’s flabby, loose skin can be improved. In addition, BodyTite also delivers double-sided skin heating (Figure 5). The handpiece features a unique external thermistor directly above the internal RF cannula tip, so directional heating occurs only between the cannula tip and the external electrode, which minimizes seroma formation.

To begin the standardized surgical procedure, a tumescent infiltration took place at a ratio of 1:1 tumescent infusion to planned lipoaspirate. In the first five patients from this series, the subcutaneous fat and volar upper arm skin were heated with the BodyTite device. Subsequently, a FaceTite device was developed (Invasix Ltd.), and the author applied this device for future patients since the smaller probe diameter and device size were better suited for the volar arm. Incisions were made in a crisscross pattern (Figure 6) to reduce the risk of overresection in the most dependent region and to reduce the “waviness” that can result from cannula lines. Five to seven treatment regions per arm were designed, measuring approximately  $7 \times 10$ - $12$  cm each. Treatment was extended 4 cm above the bicapital and tricapital grooves, and it was not totally circumferential. Treatment time with RFAL was five to 10 minutes per region. With BodyTite, the application was four to five minutes per region. Initially, the author spent about one hour per arm on multilevel heating. This operative time was reduced to about 30 minutes per arm with the newer FaceTite device, which operates on a pulsed (rather than continuous) mode due to the more superficial plane of expected treatment.

The goal of deeper heating was to obtain contraction of fibrous septae and to generate punctuate adhesions of the fat/skin complex to the underlying fascia. Three levels of heating were performed—deep, mid-level, and superficial—with more time spent at the superficial (5 mm) level to produce surface area reduction on the skin. The heating

was applied at settings of 30 to 35 watts and  $38^{\circ}\text{C}$  maximum skin temperature. An average of 4.3 kilojoules of energy was applied in each segmented treatment region. The total energy per arm ranged from 18 kJ in smaller patients to 33 kJ in patients with a larger surface area and more subcutaneous fat. End points to RF heating of a treatment region were lack of resistance, palpable warmth, and mild erythema. Visible contour changes can be intraoperatively observed with the FaceTite device, so each region was treated until protuberances were flattened without aspiration and visible skin contraction was noted. One patient from this series underwent a planned short-scar brachioplasty at the time of RF treatment due to her Stage 3 classification. The remaining 11 patients did not undergo brachioplasty; they were treated with RF heating of upper arm tissue plus aspiration only. A full summary of each patient’s classification and treatment regimen can be seen in Table 2.

All patients received a postoperative bolero-type compression garment. To obtain the smoothest possible skin contour, Topifoam (Byron Medical, Inc., Tucson, Arizona) was placed around the volar half of each patient’s arm prior to placement of the compression garment. Patients were instructed to wear the Topifoam for two weeks and the compression garment for four to six weeks postoperatively.

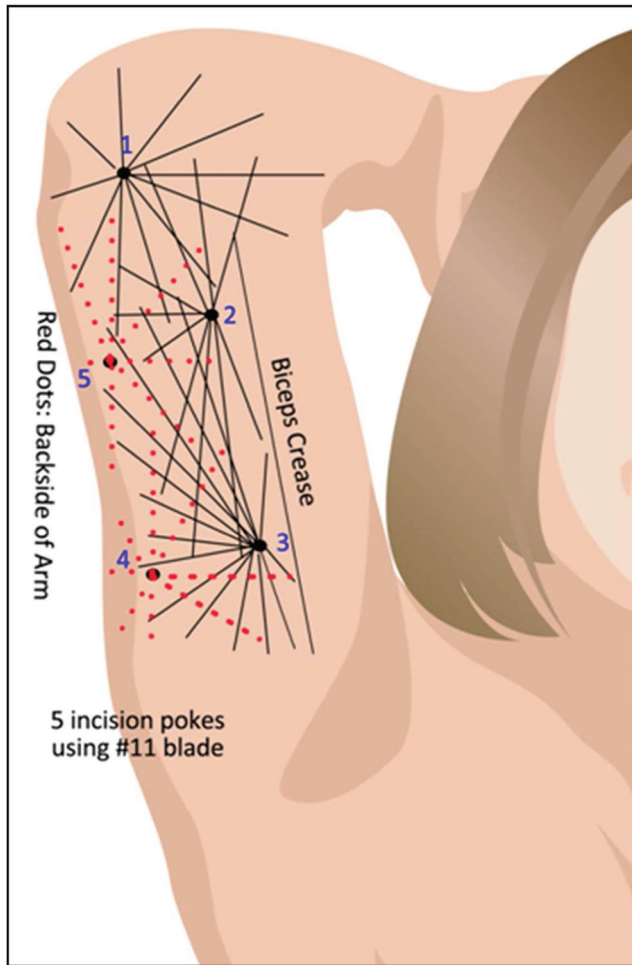
At one-year follow-up, the degree of skin surface area contraction (based on the previously-described tattoo markers) was calculated with the Vectra system (Canfield Imaging Systems, Fairfield, New Jersey) by comparing preoperative and postoperative values for four treatment areas: the proximal and distal right volar upper arms and proximal and distal left upper arms. Variability in surface area measurements can be caused with even minor postural differences, so the author made an effort to confirm each patient’s arm position as consistent to the degree possible. This objective documentation of the degree of skin contraction in the ptotic volar skin was key to evaluating the success of this new method of upper arm contouring.

Clinical results can be seen in Figures 7 to 11.

## RESULTS

Patients in this series were followed up for a minimum of one year. The average patient body mass index (BMI) was 27, and patient ages ranged from 29 to 68 years. Five patients had undergone massive weight loss (MWL), with a range of 43 to 102 pounds lost over an average period of 18 months. No patients presented with minimal deformities that would have been easily correctable with suction-assisted or ultrasound-assisted liposuction approaches. All patients were categorized as having Stage 2b, 3, or 4 deformities.

An average of 470 mL lipoaspirate was removed from each right arm, and a mean of 464 mL was aspirated from each left arm in the 12 study patients. Stage 2b patients were all successfully treated with RFAL plus suction-assisted liposuction (SAL). Although many authors



**Figure 6.** Recommended incision pattern for upper arm liposuction with radiofrequency-assisted liposuction. Note the “crisscross” pattern of aspiration, which contrasts with the common practice of aspirating from one or two access incisions located in the most dependent portion of the volar upper arm. This pattern reduces the degree of postoperative contour irregularities and the appearance of linear cannula lines.

recommend a limited brachioplasty for patients in this category,<sup>7-9</sup> all patients reported being very satisfied with the improvement in contour and the degree of volar skin laxity. Only one Stage 3 patient with extreme lipodystrophy plus extreme ptosis required a limited short-scar upper arm brachioplasty. Surprisingly, every patient in the category perceived as most commonly requiring a full traditional brachioplasty (Stage 4) was also able to be successfully treated with RFAL plus SAL alone, without the need for any skin excision. Table 3 shows the amount of volar pendulous skin laxity reduction in all 12 patients one year after treatment with RFAL.

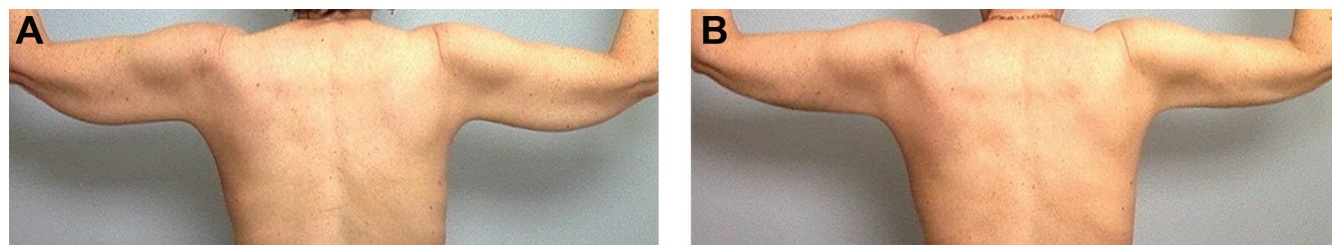
As described previously, the degree of skin contraction was assessed by comparing preoperative and postoperative values measured with the volar arm tattoo markings

**Table 2. Treatment Summary**

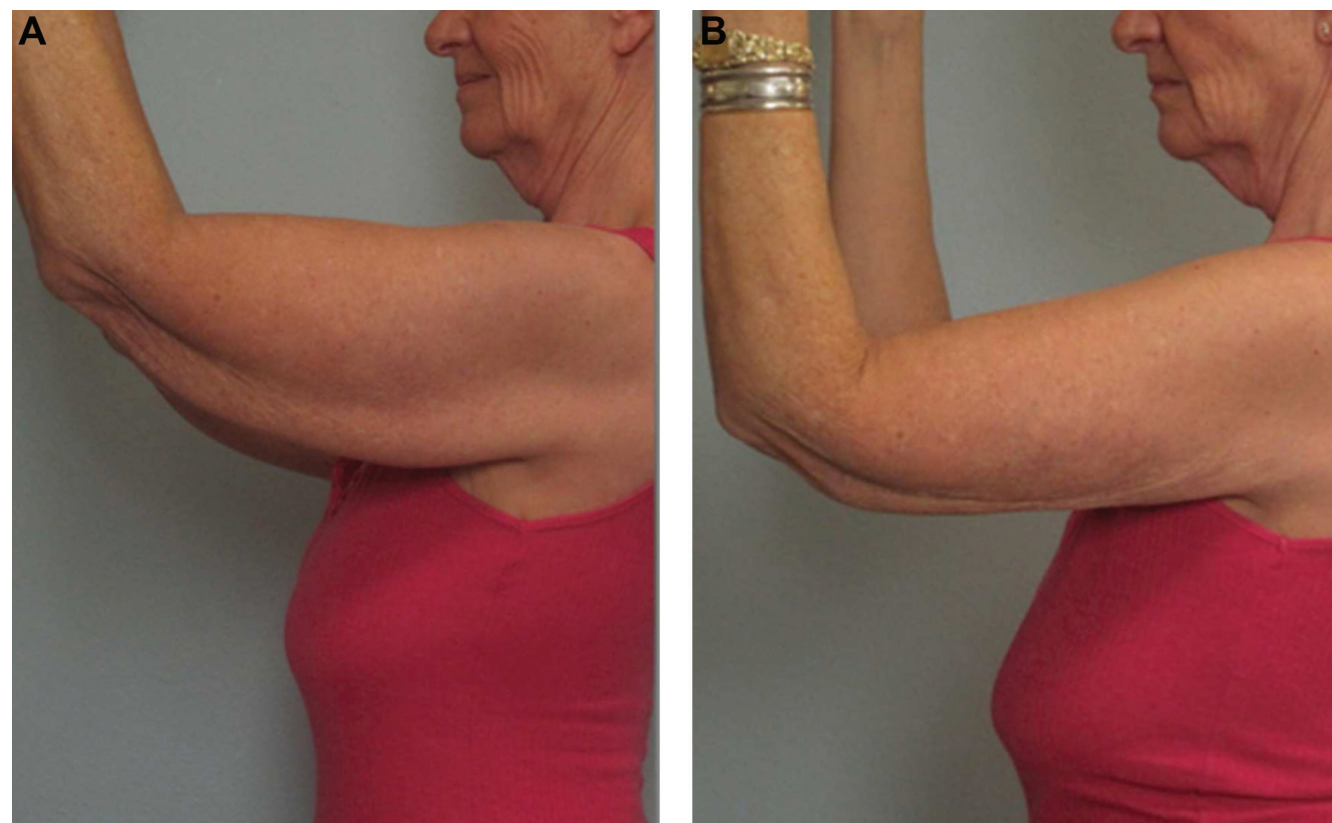Patient #	BMI	Clinical Description	Classification	Treatment
1	23.4	Thin, fit woman with skin ptosis, minimal fat deposition	Stage 4	RFAL upper arms, plus SAL
2	27	MWL (80 lb), fat plus skin ptosis, proximal striae	Stage 2b	RFAL upper arms, plus SAL
3	29.8	Stocky woman, no weight loss, with equal amount fat plus pendulous skin	Stage 2b	RFAL upper arms, plus SAL
4	26.6	Isolated upper arm deformity, no weight loss, with equal amount of fat plus pendulous skin	Stage 2b	RFAL upper arms, plus SAL
5	24	Older woman with severe skin ptosis, moderate fat	Stage 4	RFAL upper arms, plus SAL
6	19	Thin woman with little fat, pendulous skin	Stage 4	RFAL upper arms, plus SAL
7	26.6	MWL (43 lb), moderate fat plus more excess skin, proximal striae	Stage 4	RFAL upper arms, plus SAL
8	36	MWL (65 lb), equal amount fat plus pendulous skin	Stage 2b	RFAL upper arms, plus SAL
9	31	MWL (102 lb), massive upper arm fat plus skin excess >7.5 cm	Stage 3	RFAL upper arms, plus SAL; limited brachioplasty
10	31.2	MWL (80 lb), equal amount of fat plus skin	Stage 2b	RFAL upper arms, SAL
11	21	Thin woman with more skin excess than fat	Stage 4	RFAL upper arms, SAL
12	27.8	Older woman, excess fat plus very pendulous skin	Stage 2b	RFAL upper arms, plus SAL

BMI, body mass index; MWL, massive weight loss; SAL, suction-assisted liposuction; RFAL, radiofrequency-assisted liposuction.

and calculated with the Vectra system. Table 4 shows the amount of skin surface area correction achieved in this study with RFAL treatment plus SAL of the upper arms. The degree of difference in surface area was slightly higher for the distal areas (35% mean reduction in the right distal arm and 36% in the left vs 32% and 34% in the right and left proximal, respectively). There was also slightly more change noted on the right than left. However, these trends were not statistically significant.



**Figure 7.** (A) This 52-year-old woman presented for treatment of pendulous upper arm skin laxity. She was thin and fit, with a body mass index of 23.4. (B) One year after radiofrequency-assisted liposuction upper arm contouring.



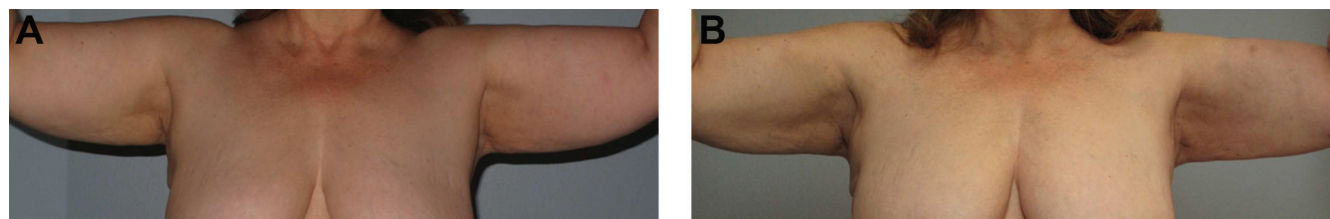
**Figure 8.** (A) This 63-year-old woman presented with a Stage 4 upper arm deformity. (B) One year after radiofrequency-assisted liposuction upper arm contouring, she demonstrates good skin contraction proximally, although the distal skin near her elbow still shows mild residual skin laxity.

## Complications

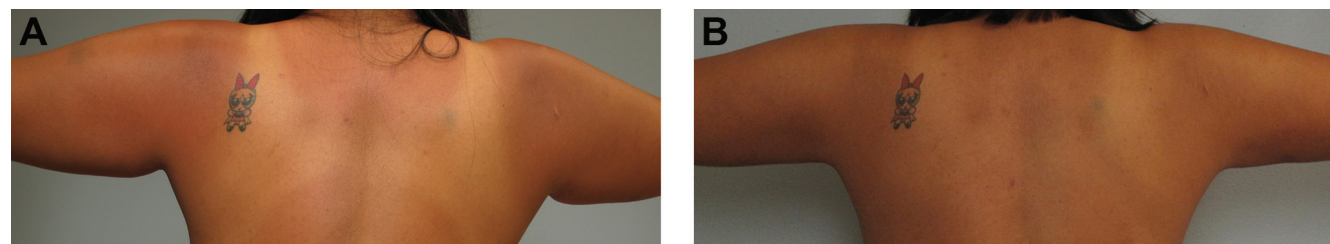
Potential complications of liposuction include numbness or hypesthesia, seroma, chronic swelling, pain, hyperpigmentation, hematoma, infection, and skin slough.<sup>10,11</sup> Unattractive access scars, a lumpy or irregular skin surface, and residual skin laxity can also occur. For those modalities relying on heat, burns can occur at the access point. “End hits” can occur if the cannula is passed too close to the skin at the furthest excursion of the stroke, causing a dermal burn or depression. Fat necrosis can occur with this procedure, noted by patients as palpable nodules.

In this study, no patient experienced prolonged numbness or hypesthesia. There were no patients with hematoma, skin slough, chronic swelling, pain, or seroma. One patient required revision of a depressed access scar. No patients experienced nodular fat necrosis in the upper arm treatment region, although this has been noted in other body regions with RFAL. There were no instances of skin contour irregularity that required revision. Three patients noted mild residual skin laxity but did not request skin excision. Two patients noted little to no improvement of proximal striae. These patients were subsequently treated with up to three sessions of profractional XC laser (Sciton, Inc., Palo Alto, California).

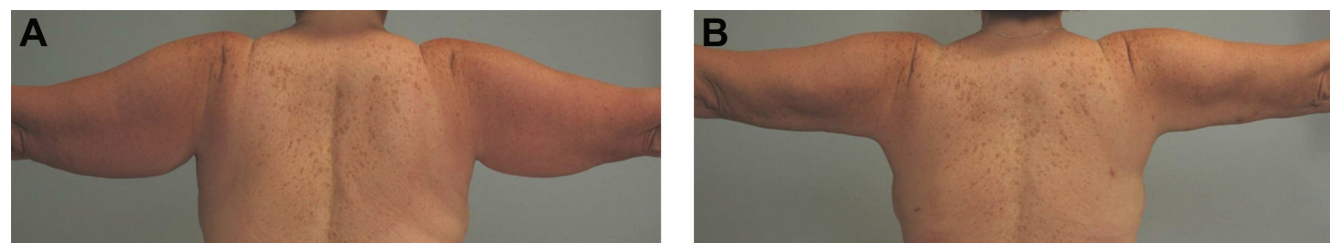




**Figure 9.** (A) This 59-year-old woman presented with skin laxity and residual fat after 65-pound weight loss. (B) One year after radiofrequency-assisted liposuction.



**Figure 10.** (A) This 31-year-old Native American woman presented with proximal skin laxity following 80-pound weight loss. (B) One year after radiofrequency-assisted liposuction of the upper arms.



**Figure 11.** (A) This 53-year-old woman presented with no weight loss, lipodystrophy, and skin excess. (B) One year after radiofrequency-assisted liposuction to both upper arms.

## DISCUSSION

One condition of IRB approval for a human scientific study is that the expected outcomes of the treatment modality being studied must not be significantly inferior to existing treatments. Although the ideal scientific study model is prospective and randomized, independent review of our protocol by physicians and the IRB concluded that the lack of acceptance by potential patients to have only one arm treated with RFAL justified our decision to treat both arms with the same modality. Furthermore, the goal of this study was not to compare RFAL to SAL but to measure the degree of skin contraction to determine whether RFAL could be successful in reducing the number of brachioplasties required for patients with more challenging upper arm deformities.

Another concern regarding RFAL involves the perception that there is a steep learning curve for surgeons. Although the BodyTite device is more difficult to apply

than SAL or power-assisted liposuction (PAL), it is similar to Vaser (Sound Surgical Technologies, Ltd., Lafayette, Colorado) and laser-assisted liposuction (LAL). The latter two approaches, which rely on energy assistance, are used for both pretunneling and heating prior to aspiration. Practitioners who have experience with some type of energy-assisted liposuction device often find that the learning curve for RFAL is relatively short. The large BodyTite device is awkward for use in the upper arm region, but the FaceTite and NeckTite handpieces are smaller and easier to apply. PAL and SAL for upper arm contouring can lead to skin contour irregularities such as cannula lines, focal residual fat pockets, and an acquired “cellulite” appearance of the thin volar skin, but energy-assisted liposuction can melt superficial fat rather than avulsing it, leaving a smoother skin surface.

One shortcoming of this study is the small patient cohort. Independent statisticians involved with this study performed several calculations to confirm that the results



Table 3. Skin Protrusion Analysis

Patient #	Caliper Skin Laxity Preoperative Right Arm	Caliper Skin Laxity Postoperative Right Arm	% Decrease	Caliper Skin Laxity Preoperative Left Arm	Caliper Skin Laxity Postoperative Left Arm	% Decrease	Difference Right/Left, cm
1	4.7	3.0	36	4.6	2.9	37	1.7/1.7
2	5.3	3.2	40	4.9	2.9	41	2.1/2.0
3	5.7	3.1	46	5.5	2.9	47	2.6/2.6
4	5.1	2.0	61	5.3	2.2	58	3.1/3.1
5	5.6	3.8	32	5.7	3.9	32	1.8/1.8
6	3.8	1.6	58	4	1.7	58	2.2/2.3
7	4.8	2.7	44	4.7	2.5	47	2.1/2.2
8	5.7	2.5	56	5.5	2.4	56	3.2/3.1
9	6.5	4.5	31	6.7	4.8	28	2.0/1.9
10	5.2	1.8	65	5.1	2.0	61	2.0/2.1
11	4.3	1.7	60	4.5	1.8	60	2.6/2.7
12	5.4	1.8	67	5.6	1.9	49	3.6/3.7
Mean value	5.18	2.64	50	5.18	2.64	50	2.25/2.275
Standard deviation	0.71	0.92	13	0.71	0.88	12	
P value			1.75E (-8) <.001			1.05E (-8) <.001	
Confidence interval			2.16-2.91			2.17-2.89	

Confidence level for this table is 93%.

achieved were indeed statistically significant. Accordingly, we found that the probability that the results would be the same in a repeat study was approximately 93.5%; this number was supported by the interpatient consistency of results and a low level of standard deviation from the mean, as well as consistency of results between the right and the left sides.

Many devices claim to result in aesthetic skin tightening. However, scientific proof for these claims is sparse. Objective measurements of skin surface contraction have often been performed by noting the distance between two fixed points such as pigmented lesions, scars, or anatomic landmarks.<sup>12</sup> However, methods of measuring skin surface area with tattoos have become more sophisticated and more accurate in comparison to early methods. It should also be noted that traditional skin fold thickness calipers can be loosely or tightly crimped and do not measure the degree of skin laxity, but most practitioners do not have 3D photographic analysis mechanisms or devices to measure skin quality in the office setting. Therefore, a simple and reproducible measurement method has long been needed for clinically assessing the difference in the degree of pendulous “hang” preoperatively and postoperatively, after upper arm contouring.

To determine the degree of skin laxity, the degree of pendulous ptosis should be measured at a fixed point with

an unchanging base thickness. To make this clinical measurement as reproducible as possible for this study, a fixed point 7 cm from the deepest anterior axillary depression was drawn at the base of the bicipital groove. Furthermore, based on the “pinch” test and on El Khatib’s measurement<sup>1</sup> of upper arm skin ptosis, a new device was devised for reliably and accurately measuring the amount and thickness of hanging, pendulous skin. The skin protrusion measuring device was used to generate a skin fold thickness that could be reproduced with each subsequent measurement. The standard base thickness used in this study was 2.5 cm; a hem-gauge-type ruler extending from the base of the skin fold caliper was used to measure the vertical height of hanging skin. Postoperative measurements were taken at the same point, and the same 2.5-cm skin fold base thickness was recreated. The length of pendulous skin was again measured to assess the degree of reduction in skin laxity. Although this device is clearly not perfect, it is reliable enough to document a significant change in skin laxity before and after treatment.

Similarly, B. DiBernardo (personal communication, May 2010) showed different levels of response to LAL treatment in different regions of the abdomen; this study was designed similarly to determine whether the same differences could be observed in the proximal or distal

Table 4. Skin Surface Area Reduction

Patient #	Preoperative: Right Distal	Postoperative: Right Distal	% Difference	Preoperative: Right Proximal	Postoperative: Right Proximal	% Difference	Preoperative: Left Proximal	Postoperative: Left Proximal	% Difference	Preoperative: Left Distal	Postoperative: Left Distal	% Difference
1	4.22	2.45	42	4.34	2.74	37	4.27	2.61	39	4.06	2.23	45
2	4.41	3.16	28	4.36	3.52	19	4.60	3.71	19	4.72	3.38	28
3	9.03	6.55	27	9.22	6.89	25	9.07	6.70	26	8.94	6.11	32
4	9.13	5.97	35	9.22	6.16	33	9.31	6.04	35	9.08	5.89	35
5	9.17	5.33	42	9.48	5.67	40	9.31	5.52	41	9.26	5.37	42
6	4.28	3.56	17	3.99	3.14	21	4.32	3.59	17	4.15	3.43	17
7	9.16	6.37	30	9.25	6.98	25	9.32	7.01	25	8.96	6.55	27
8	9.46	6.65	30	10.11	7.38	27	9.81	6.91	30	9.17	6.74	26
9	9.13	5.68	38	9.87	6.43	35	9.74	6.22	36	9.57	6.07	37
10	9.41	5.43	42	9.55	5.85	39	9.39	5.77	39	9.11	5.41	41
11	4.25	2.45	42	4.39	2.67	39	4.51	2.43	46	4.33	2.19	49
12	4.19	2.12	49	4.22	2.26	46	4.30	2.19	49	4.13	2.09	49
Mean, cm	7.15	4.64	35	7.33	4.97	32	7.33	4.89	34	7.12	4.62	36
Standard deviation	2.55	1.76	9	2.73	1.94	9	2.59	1.85	6	2.52	1.82	10
Confidence interval			1.92-3.10			1.77-2.95			1.85-3.03			1.91-3.04
P value			1.77 E(-6) <.001			3.21 E(-6) <.001			2.39 E(-6) <.001			1.33 E(-6) <.001

Confidence level for this table is 94.5%.

upper arm. Although skin calipers were first used to measure the distance between tattoos,<sup>13</sup> DiBernardo also pioneered the use of Vectra 3D imaging in skin tightening assessment during his study of the SmartLipo device (Cynosure, Inc., Westfield, Massachusetts).<sup>14</sup>

The upper arm is a difficult region to recontour successfully. Although some patients may be satisfied with mere reduction in size, most expect much more significant changes. Many present with the assumption that a surgeon can automatically transform flabby, pendulous fat and skin into a smooth and taut surface. Even when the obstacles to success—such as skin laxity, striae, solar damage, and inelastic skin—are reviewed with the patients, they frequently do not fully understand the reality of a less-than-perfect skin surface. The goal of most women with large, sagging upper arms is a postoperative result that will give them the ability to wear short-sleeved or sleeveless clothing without being self-conscious about their appearance. Another important goal is their ability to animate without having the volar skin continue to “wiggle” once the intentional arm motion ceases. Even if the surgeon is able to achieve reduction of upper arm fat or circumference, the positive results will not be appreci-

ated if residual skin laxity, cannula lines, “cellulite,” or unattractive scars or depressions are present following treatment. If the degree of flabbiness upon animation is not significantly reduced, patients will most certainly be dissatisfied.

In their early review of treatment for upper extremities with liposuction, Pitman and Teimourian<sup>15</sup> noted a 21.7% rate of unsatisfactory results. In the great majority of cases, residual skin excesses were noted as the primary problem. The authors suggested skin excision—not liposuction—as a solution. Although the majority of patients prefer less invasive surgery and less significant scarring, minimally-invasive approaches have not always resulted in satisfactory outcomes in the upper arm region. Uncorrected skin laxity has been the most frequent patient complaint, followed by postliposuction contour irregularities.<sup>16</sup> Cannula lines, depressions and protrusions, and puckering scars have also led patients to complain of unsatisfactory postoperative results that still prevent them from wearing clothing that exposes their upper arms. Patients may express regret, indicating that they would not have elected to undergo surgery if they had known that they would be trading one problem

(disproportionately large upper arms) for another (smaller arms with depressions, protrusions, cannula lines, and residual skin laxity).

A number of liposuction methods have been documented in the literature. Schlesinger<sup>17</sup> proposed a four-cannula technique for upper arm liposuction. The cannulas, all with a diameter of 3 mm or less, were of varying lengths, which enabled the surgeon to utilize a single incision. In 1994, Gasperoni and Salgarello<sup>18</sup> advocated massive all-layer liposuction (MALL) as a means of enhancing skin retraction. This technique was developed as an expansion of superficial subdermal liposuction. The authors advocated “unweighting” the skin by combining superficial liposuction with deep, multilevel aspiration. Gilliland and Lyos<sup>19,20</sup> introduced the Circumferential Para-Axillary Superficial Tumescent (CAST) method as a nonexcisional alternative for lipoaspirating the axilla and upper extremities. The authors utilized a circumferential tumescent technique either in place of brachioplasty or as a pretreatment to reduce the extent of brachioplasty. They felt that maximal skin retraction could be achieved through a more superficial and circumferential approach than is traditionally performed.

In another article, Lillis<sup>21,22</sup> advised managing patient expectations before proceeding with arm liposuction. Although dramatic skin contraction can be achieved in most patients, he noted that “textural” changes also occur. Surgically, he recommended complete aspiration of fat to prevent contour irregularity. A two-stage approach—liposuction first, followed by a second liposuction or brachioplasty—was his preference for treating patients with massive arms. In an effort to similarly improve the smoothness of the skin surface, de la Plaza and Arroyo<sup>23</sup> utilized a “tunnel tracer” and a set of guided cannulas.

A newer method of achieving skin contraction in upper arms involves LAL.<sup>24</sup> Dudelzak et al<sup>24</sup> claimed that liposuction is traumatic and leaves residual skin laxity, whereas LAL can provide tissue tightening. They studied 20 female patients treated with tumescent LAL, applying a SmartLipo laser with a 300-micron fiber alone or in combination with SAL in half of the patients. Unfortunately, postoperative measurements included arm circumference alone, and no direct comparison of SAL versus LAL results was performed. Prado et al<sup>25</sup> did compare LAL to SAL in a 25-patient study performed in 2005. The authors treated multiple regions of the body and randomly selected the patient’s left or right side to receive treatment with LAL; the opposite side was assigned SAL treatment. A graded system of cosmetic evaluation was used to determine that there was no difference in aesthetic outcome between these two modalities. Although it was not specific to the upper arms, DiBernardo’s study<sup>26</sup> measuring the degree of skin contraction with LAL established scientific parameters for measuring skin contraction following nonexcisional lipectomy.

Other methods of liposuction have been designed to reduce surgeon fatigue (PAL) or ease the passage of the cannula into stiff or fibrous fat (ultrasonic-assisted

liposuction [UAL] and Vaser).<sup>27</sup> Although initially thought to cause greater skin retraction than SAL due to accompanying heat, UAL has not been shown to provide a measurable difference in skin contraction or skin quality compared to more traditional modalities.<sup>29</sup>

In terms of limitations, Pitman and Temourian<sup>30</sup> reported SAL complications such as numbness or hypesthesia, seroma, chronic swelling, pain, hyperpigmentation, hematoma, infection, and skin slough. Dillerud,<sup>29</sup> in his study of 3511 liposuction patients, noted a 1.2% incidence of complications. A range of 0.1% to 5.8% has been reported from various other authors.<sup>11,30-32</sup> Dillerud classified postoperative cosmetic problems such as unattractive access scars, a lumpy or irregular skin surface, and residual skin laxity as “undesired results.” Both Dillerud and Pitman each quoted a 9% to 10% incidence of revisional surgery following liposuction. However, the incidence of mild to moderate scar deformity, protrusions and depressions in the skin contour, and mild patient dissatisfaction with the degree of skin tautness following traditional liposuction is very common, although they do not always require surgical revision. These are expected sequelae and are treated if requested by the patient. The concept of “lipo repair”—applying minimally-invasive techniques such as fat grafting, internal lipomobilization, and subcision to correct skin contour irregularities<sup>33</sup>—has become more common and is frequently utilized in place of further liposuction.

Cosmetic sequelae have also been noted following LAL. For example, a patient with thin skin underwent very superficial LAL treatment and subsequently reported cannula lines, irregular fat distribution, and skin contour irregularities reminiscent of cellulite. When used in a large treatment region, LAL is tedious; therefore, it is frequently applied in conjunction with SAL to produce a more dramatic fat reduction.

RFAL, if not applied correctly, can yield similar problems to those seen with more traditional methods since liposuction accompanies the heating procedure. RFAL is similar to LAL and Vaser in that a small amount of fat is thermally lysed as the cannula is passed. There is a suction device within the cannula that aspirates heated fat, thus reducing the risk of seroma or local tissue burn, but in larger-volume cases, SAL or PAL is often applied to further improve the patient’s contour, so the same risks apply.

## CONCLUSIONS

In this pilot study, 12 patients underwent upper arm treatment with RFAL. Comparison of preoperative and one-year postoperative caliper and skin tattoo measurements showed a 50% average reduction in vertical height of the pendulous skin laxity and an average skin surface area contraction of 33.5%. There were no complications in this series that required reoperation. One patient requested revision of a depressed access scar. No patient reported visible cannula lines, focal depressions, or protrusions in the treatment



region, nor did they report any unsatisfactory outcome. All patients noted a visible degree of skin tightening. On the basis of these results, the author provided a revised classification and treatment algorithm for upper arm deformities that reflects her recommendation for fewer brachioplasties when contouring in this region can be performed with RFAL. The majority of patients in Categories 2b and 4 of the algorithm can successfully be treated without the need for additional excisional procedures, providing a less-invasive alternative for patients who present for aesthetic treatment of their upper arms.

### Acknowledgment

Statistical analysis was provided by Rebecca and Gary Walls.

### Disclosures

Dr. Duncan is a consultant for Invasix, the manufacturer of products discussed in this study.

### Funding

The author received no financial support for the research, authorship, and publication of this article.

### REFERENCES

1. El Khatib H. Classification of brachial ptosis: strategy for treatment. *Plast Reconstr Surg* 2007;119:1337-1342.
2. Teimourian B, Malekzadeh S. Rejuvenation of the upper arm. *Plast Reconstr Surg* 1998;102:545-551.
3. Appelt E, Janis J, Rohrich R. An algorithmic approach to upper arm contouring. *Plast Reconstr Surg* 2006;118:237-246.
4. Illouz Y, DeVillers Y. *Body Sculpting by Lipoplasty*. Edinburgh, UK: Churchill Livingstone; 1989:172-178.
5. Sacks A. Grading system simplifies brachioplasty decisions. *Cosmetic Surgery Times* March 2003:8.
6. Blugerman G, Schavelzon D, Paul M. A safety and feasibility study of a novel radiofrequency-assisted liposuction technique. *Plast Reconstr Surg* 2010;125:998-1006.
7. Cannistra C, Valero R, Benelli C, Marmuse JP. Brachioplasty after massive weight loss: a simple algorithm for surgical plane. *Aesthetic Plast Surg* 2007;31:6-9.
8. Gusenoff J, Coon D, Rubin JP. Brachioplasty and concomitant procedures after massive weight loss: a statistical analysis from a prospective registry. *Plast Reconstr Surg* 2008;122:595-603.
9. Lockwood T. Brachioplasty with superficial fascial system suspension. *Plast Reconstr Surg* 1995;96:912-920.
10. Gorney M. Sucking fat: an 18-year statistical and personal retrospective. *Plast Reconstr Surg* 2001;107:608-613.
11. Teimourian B, Rogers WB. A national survey of complications associated with suction lipectomy: a comparative study. *Plast Reconstr Surg* 1989;84:628-631.
12. Mulholland S. Radiofrequency-assisted liposuction instructional course. November 2008, Toronto, Canada.
13. Duncan DI. The evolution of mesotherapy. Paper presented at the ASPS Breast and Body Contouring Symposium, August 2006, Santa Fe, NM.
14. DiBernardo B, Reyes J. Evaluation of skin tightening after laser-assisted liposuction. *Aesthetic Surg J* 2009;29:400-407.
15. Pitman G, Teimourian B. Suction lipectomy: complications and results by survey. *Plast Reconstr Surg* 1985;76:65-69.
16. Matarasso SL. A regional approach to patient selection and evaluation for liposuction. *Dermatol Clin* 1990;8:401-414.
17. Schlesinger SL. Suction-assisted lipectomy of the upper arm: a four cannula technique. *Aesthetic Plast Surg* 1990;14:271-274.
18. Gasperoni C, Salgarello M. MALL liposuction: the natural evolution of subdermal superficial liposuction. *Aesthetic Plast Surg* 1994;18:253-257.
19. Gilliland MD, Lyos AT. CAST liposuction of the arm improves aesthetic results. *Aesthetic Plast Surg* 1997;21:225-229.
20. Gilliland MD, Lyos AT. CAST liposuction: An alternative to brachioplasty. *Aesthetic Plast Surg* 1997;21:398-402.
21. Lillis PJ. Liposuction of the arms. *Dermatol Clin* 1999;17:783-797.
22. Lillis PJ. Liposuction of the arms, calves, and ankles. *Dermatol Surg* 1997;23:1161-1168.
23. de la Plaza R, Arroyo JM. The rationalization of liposuction: toward a safer and more accurate technique. *Aesthetic Plast Surg* 1989;13:243-250.
24. Dudelzak J, Hussain M, Goldberg DJ. Laser lipolysis of the arm with and without suction aspiration: clinical and histologic changes. *J Cosmet Laser Ther* 2009;11:70-73.
25. Prado A, Andrades P, Danilla S, et al. A prospective, randomized, double-blind controlled clinical trial comparing laser-assisted lipoplasty with suction-assisted lipoplasty. *Plast Reconstr Surg* 2006;118:1032-1045.
26. DiBernardo B. Randomized, blinded split abdomen study evaluating skin shrinkage and skin tightening in laser-assisted liposuction versus liposuction control. *Aesthetic Surg J* 2010;30:593-602.
27. Maxwell GP, Gingrass MK. Ultrasound-assisted lipoplasty: a clinical study of 250 consecutive patients. *Plast Reconstr Surg* 1998;101:189-202.
28. Dillerud E. Suction lipoplasty: a report on complications, undesired results, and patient satisfaction based on 3511 procedures. *Plast Reconstr Surg*. 1991;88(2):239-46; discussion 247-9.
29. Fodor PB, Watson J. Personal experience with ultrasound-assisted lipoplasty: a pilot study comparing ultrasound-assisted lipoplasty with traditional lipoplasty. *Plast Reconstr Surg* 1998;101:1103-1116.
30. Pitman G, Temourian B. Suction lipectomy: complications and results by survey. *Plast Reconstr Surg* 1985;76:65-69.
31. Illouz YG. Complications de la lipoaspiration. *Annales de chirurgie plastique esthetique* 2004;49:614-629.
32. Newman J, Dolsky RL. Evaluation of 5458 cases of liposuction surgery. *Am J Cosmet Surg* 1984;1:25-80.
33. Teimourian B, Rogers WB. A national survey of complications associated with suction lipectomy: a comparative study. *Plast Reconstr Surg* 1989;84:628-631.
34. Sommer B, Bergfeld D, Sattler G. Liporepair: approach to correction of fat tissue deformities. *Hautarzt* 2004;55:605-610.